

# **EMBRYOLOGY OF THE UPPER LIMB**

**Dr Vasudeva Reddy. D ([danduruvasudevareddy@gmail.com](mailto:danduruvasudevareddy@gmail.com)) –**

*Fellow in Hand and Microsurgery, Ganga Hospital, Coimbatore.*

**Dr Aashish Vallurupalli ([ashi.rmc@gmail.com](mailto:ashi.rmc@gmail.com)) –**

*Fellow in Hand and Microsurgery, Ganga Hospital, Coimbatore.*

**Dr Praveen Bhardwaj ([drpb23@gmail.com](mailto:drpb23@gmail.com)) –**

*Consultant Hand Surgery, Ganga Hospital, Coimbatore.*

The prevalence of congenital hand anomalies is approximately 1 in 500<sup>1</sup>. The incidental studies have shown different prevalence in different populations and geographical areas<sup>1</sup> (Triphalangeal thumb is common in Netherlands). As all the events of limb formation occur between 4<sup>th</sup> and 8<sup>th</sup> week, this incidence seems less when compared to the velocity of proliferative and differentiating events that occur during this 4 weeks interval. It denotes how well the embryogenesis is genetically programmed. Embryology of the upper limb is of extreme importance as it helps the surgeon to understand the pathogenesis and probable causes of numerous congenital hand differences.

Congenital hand anomalies are second only to congenital heart defects in incidence. The limb bud and heart development in the embryo are regulated by a common gene - (TBX 5)<sup>2</sup>. Some congenital anomalies go undetected because of their not so obvious nature (Camptodactyly and grade I hypoplastic thumb) and some conceptions with congenital hand anomalies will get spontaneously aborted because of chromosomal aberrations that are incompatible with life. Hence true incidence can never be quantified.

## **WHAT ARE THE DUTIES OF A HAND SURGEON IN A CASE OF CONGENITAL HAND ANOMALY?**

The parents of the affected child face a tremendous mental, social and economic burden during the course of treatment. It is the prime duty of a hand surgeon to guide and assure the parents at the initial consultation itself. He/ She should explain various reconstructive options available for the correction of a particular hand anomaly and should always reassure them that most of the children will be able to cope up with the peer group in almost all activities (excluding the severe anomalies). Parents should also be counselled regarding the chances of the deformity in the next conception. Genetic counselling and karyotyping may also need to be stressed in some anomalies which are known to occur in the next child due to autosomal dominant inheritance (Split hand and foot syndrome).

### **EMBRYOLOGY:**

Clear understanding of the events involved in the limb bud evolution is very important before studying any congenital hand anomaly. The intricate genomic and protein (growth factors) interactions involved in the limb bud progression is clearly understood in the recent past following tremendous experimentation on animal embryos.

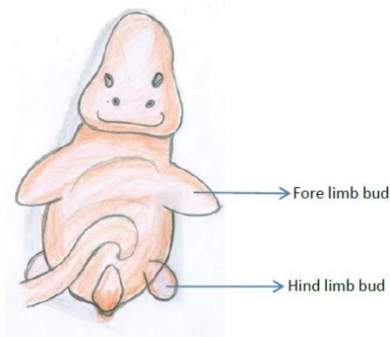
#### **How limb bud formation is induced?**

Limb bud forms relatively late during the embryogenesis after all trunk structures are reasonably well formed during 4th week <sup>3</sup>(*fig1,2, table 1*).

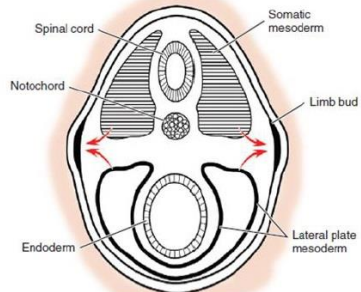
**Theory 1:** Axial skeleton produce FGF 10 (Fibrinogen growth factor) which induces extrusion of ectoderm and mesoderm to form limb bud. In mice embryo experiments when FGF releasing bead is implanted on non-limb site, it induced extra limb on the flank. Induced mutation in FGF 10 gene resulted in amelia in chick embryo. High expression of FGF8 in the ectoderm had also been thought to induce limb bud formation by some researchers.

**Theory 2:** On 26th/27th day following fertilisation notochord secretes Sonic Hedge Hog (SHH) protein which stimulates the extrusion of ectoderm and mesenchyme on ventro-lateral aspect of embryo. This limb bud is located near the cervical somites on either side of embryo.

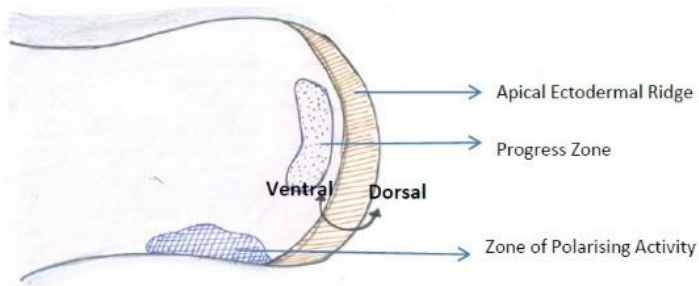
Two types of mesenchyme enter limb bud to form mesodermal structures. Lateral plate mesoderm forms cartilage, bones and tendons while somatic mesoderm forms muscles, and arteries (*fig 3*).



*Fig 1: Embryo with limb bud*



*Fig 2: Cross section of embryo*



*Fig 3: Limb bud sagittal section*

Intra Uterine day	Event
21-22 <sup>nd</sup> day	Notochord expresses SHH
26-27 <sup>th</sup> day	Limb bud appears on ventrolateral aspect of trunk (embryo length-4mm)
31 <sup>st</sup> day	Hand segment recognizable
36 <sup>th</sup> day	Splitting of hand plate to digital rays and fissures. First 3 central rays followed by border digits.
48 <sup>th</sup> day	All skeleton of the hand is cartilaginous except terminal phalanx. Digits are well formed differentiated. Thumb diverges out. Cavitation occurs in wrist and digits.
54 <sup>th</sup> day	Completely formed fingers and ossification of humerus. No further differentiation

*Table 1: Milestones of hand development during intrauterine period. (SHH – Sonic hedgehog)*

## **PARTS OF LIMB BUD**

### **Apical Ectodermal Ridge (AER):**

This is the thickened ectoderm at the tip of progressing area of limb bud (*fig-3*). It is the main regulating area for proximal to distal growth pattern of limb through the proteins secreted by it. AER formation is induced by undifferentiated mesenchyme in the initial stage and later controlled by cells of progress zone (PZ). Any disturbance in the loop results in abrupt termination of limb due to AER suppression.

AER produces FGF 8 in the early stages which will take over the function of axial structures that initiate limb bud formation. Later several different types of FGFs are produced (FGF2,4,9&17) which will continue inducing proximo-distal limb growth.

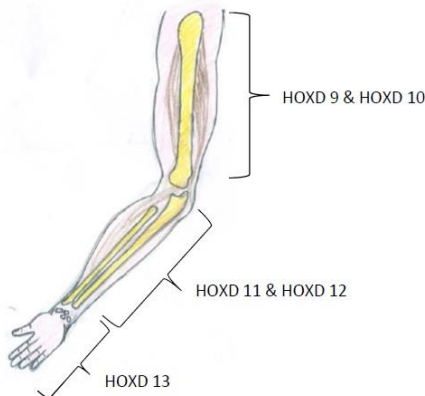
### **Progress Zone (PZ):**

A group of specialised mesenchymal cells underneath AER form Progress Zone (PZ). It is the main determinant for actual structures that mesenchymal cells form during the course of limb bud growth. For example, when PZ cells of wing bud is replaced with leg bud cells, wing

bud formed leg structures. Hence undifferentiated mesenchyme of limb bud can form either wing or leg structures depending on type of PZ (Wing/Leg). Cells in this zone sequentially form arm, forearm and hand. The cells that stay long in this zone will form hand whereas the cells that leave early form arm. For example, when PZ cells of older limb bud is transplanted in a young limb bud it formed only hand without arm and forearm, and when a young limb bud PZ cells are transplanted in to old limb bud it formed duplicated arm and forearm without hand. Hence it acts as an internal clock for limb bud segmentation. It is regulated by genes HOX A and HOX D. These genes are expressed sequentially with some overlap. The limb is segmented into 3 main zones. Each zone will be formed when dominant expression of particular gene subtype is present (*table 2, fig 4*).

<b><i>Segment</i></b>	<b><i>Controlling Gene</i></b>
Zeugopod (arm)	HOXD 9 and HOXD 10
Stylopod (forearm)	HOXD 11, HOXD 12 and HOXD 13
Autopod (hand)	HOXD 13

*Table 2: Segmentation of limb and controlling genes.*



*Fig 4: Segmentation of limb and genes controlling it.*

**Zone of Polarising Activity (ZPA):**

This is a specialised mesenchymal tissue located posteriorly in the limb bud which governs antero-posterior orientation of limb during intra-uterine life. It secretes Sonic Hedge Hog (SHH) protein which is diffusible through the mesenchyme. The mesenchyme exposed to higher concentration of SHH (posterior mesenchyme) will form the ulnar side (post axial) skeleton while mesenchyme exposed to low concentration (anterior mesenchyme/away from ZPA) will form the radial side (pre axial) skeleton.

**SPATIAL ORGANISATION OF UPPER LIMB**

Limb growth and tissue differentiation occurs in 3 planes: Proximo-distal (PD), antero-posterior (AP) and dorso-ventral (DV) (*fig 5*). Among these axis, AP axis is defined first followed by DV axis and PD axis is the last one to be defined<sup>1</sup> (*table 3*).

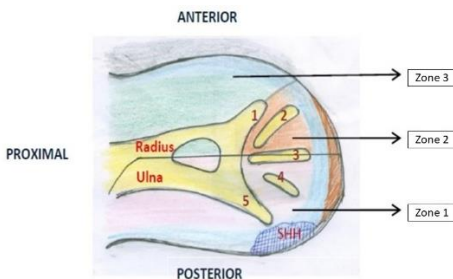
Axis and Signaling Centre	Action	Proteins & Transcription factors Involved
Dorsoventral (WNT pathway)	Differentiation of dorsal and ventral structures	Ventral ectoderm expresses EN-1 Dorsal ectoderm expresses WNT7
Anteroposterior (ZPA)	Differentiation of ulnar and radial structures	ZPA expresses SHH. Other markers include GL13A, FGF 10 and MSX 1
Proximo-distal (AER)	Growth from proximal to distal	AER expresses FGF 8, FGF 4,FGF 2 and WNT3A

*Table 3: Proteins and factors controlling spatial organisation of the upper limb.*

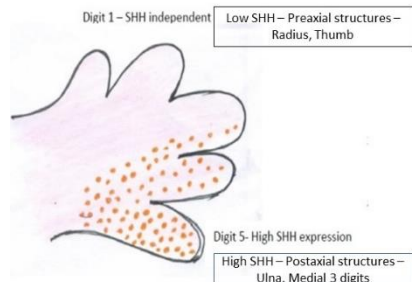
(Wnt – Wingless integration gene)

## ANTERO-POSTERIOR AXIS:

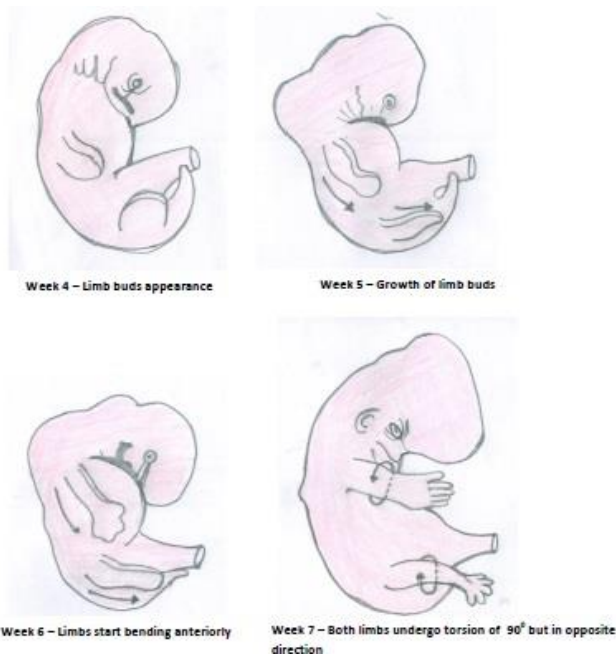
It is defined even before limb bud is formed by the specialised mesenchymal cells which will form posterior mass in future limb bud. They secrete SHH protein that stimulates transcription factors in the cells that are near to it forming ulnar/post-axial structures (*fig 5,6*). Other part of limb bud away from SHH forms radial/pre-axial structures<sup>5</sup>. The antero posterior axis can be divided into 3 zones, zone 1 is the area contains descendants of SHH expressing cells and is responsible for development of the ulna, the little finger, the ring finger, the ulnar half of middle finger and the ulnar 2 columns of carpals. Zone 2 is under the influence of long range SHH signalling (i.e, the diffusible SHH protein) and is responsible for the development of the radial part of middle finger and the index finger. Zone 3 consists of the radius, radial column of the carpals and the thumb, which will develop normally only in the absence of SHH activity (*fig 5*). The reader should not get confused thinking how radial structures are anterior in embryo. This can be explained by limb rotation that occurs during 7th week of life where limb bud (anteriorly placed radial and posteriorly placed ulnar structures) undergoes 90 degrees rotation bringing adult anatomical position (radial structures are lateral and ulnar structures are medial) (*fig 7*).



*Fig 5: ZPA (SHH) and role in AP axis determination.*



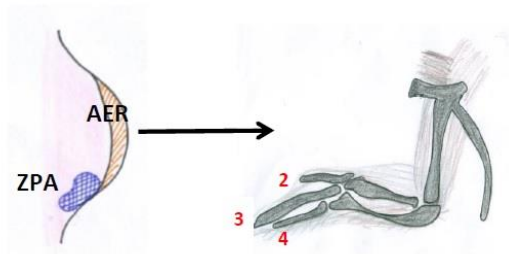
*Fig 6: SHH concentration and digits.*



*Fig 7: Limb rotation in embryo.*

Normal chick wing skeleton will have 3 digits 2, 3 & 4 in anterior to posterior pattern. Digit formed near to ZPA is 4 while digit formed away will be digit 2 (*fig 8*). In chick embryo experiments when retinoic acid bead was placed anteriorly which simulates SHH activity, it induced formation of 3 extra digits in mirror image symmetrical pattern (4,3,2,2,3,4). But often the central duplicated rays are either malformed or fused (*fig 9*). This explains the pathogenesis of mirror hand.

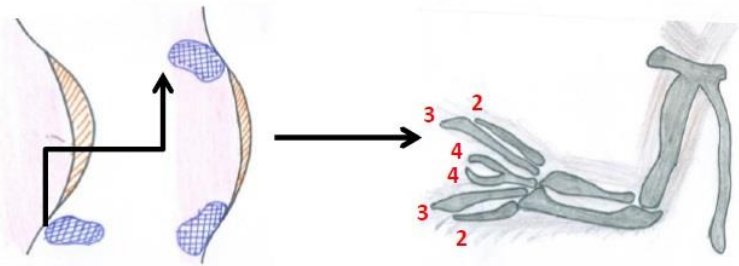




*Fig 8: Normal chick embryo wing bud.*

Donor limb bud

Host limb bud



*Fig 9: Anomaly induced by transplanting ZPA anteriorly.*

## **DORSO-VENTRAL AXIS:**

Our ventral skin is peculiar in having glabrous palmar skin and relatively less hairy forearm skin with flexural creases. Whereas the dorsal skin is thin, hairy and pinchable. This differentiation is modulated by the ectoderm. The ventral ectoderm expresses Engrailed 1 (EN 1) which inhibit this Wnt 7 mediated signal in ventral part and supports formation of ventral structures whereas Wnt 7(Wingless type 7) expressed by dorsal ectoderm supports dorsal structures formation through LMX 1B transcription factor (*fig 10*). In Nail-patella syndrome this LMX 1B gene is defective leading to abnormal dorsal structures (nails and patella)<sup>4</sup>.

Wnt 7 also maintain SHH expression posteriorly. When ectoderm is separated from limb bud and implanted on the opposite bud the dorsal and ventral surfaces reversed in chick embryo indicating its importance in DV axis formation.

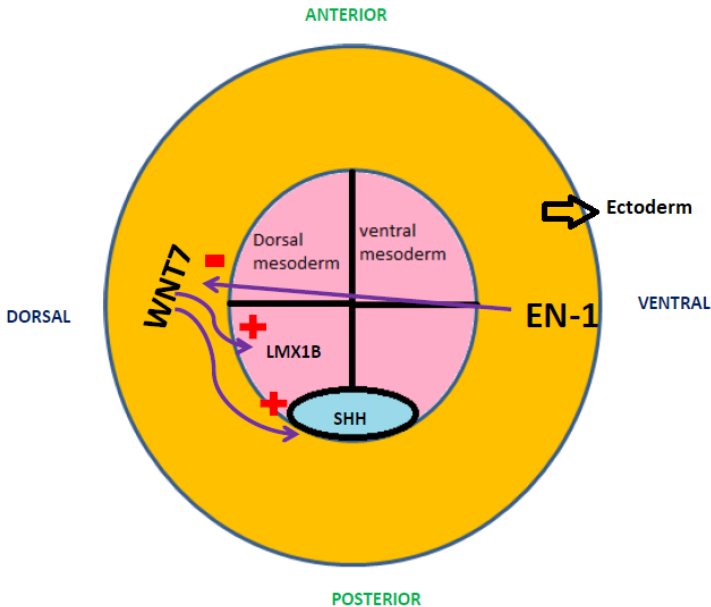
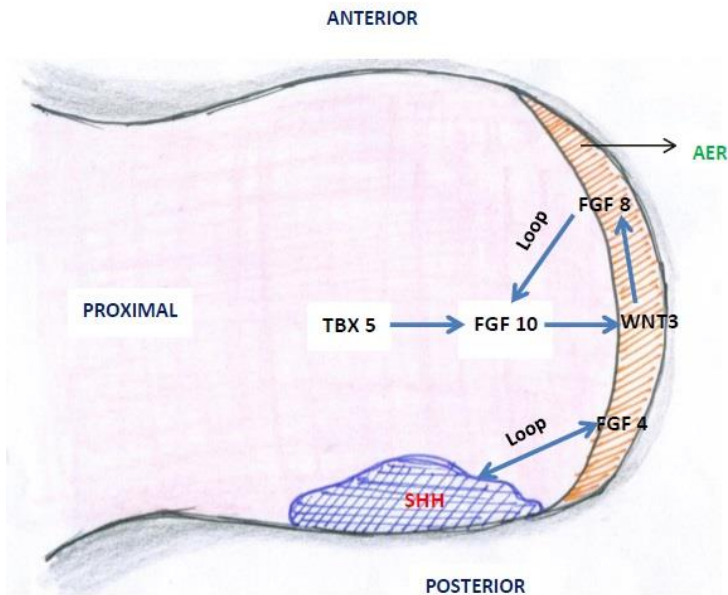


Fig.10: Dorso-ventral axis and role of ectoderm.

### **PROXIMO-DISTAL AXIS:**

Early mesoderm of limb bud expresses TBX5 (T-Box5) which in turn stimulates mesodermal FGF10. This FGF10 stimulates AER through WNT3 to produce FGF8. This is called FGF8-FGF10 loop which maintains PD axis (*fig 11*). Posterior part of AER is induced to produce FGF4 by SHH which is produced in the posterior mesoderm. This is called SHH-FGF4 loop and this maintains expression of SHH (ZPA).

Amelia result from early truncation of AER either due to ischaemia or teratogens and split hand and foot syndrome results from injury to central portion of AER.



*Fig.11: Role of AER in proximo-distal axis and interaction with ZPA.*

### **Formation and differentiation of the hand plate:**

The hand plate becomes visible around the fifth week of development. The HOX transcription factors (particularly HOXD9-13, HOXA9-13) and SHH interact to establish digit number and identity. The SHH (Sonic Hedgehog) is governed by ZPA mesenchymal cells controlling the posteroanterior differentiation as described above. This determines the ulnar and radial digits. This SHH also induces the BMP (Bone Morphogenetic Protein) gradient across the posteroanterior axis that has at least 2 major roles in digit formation and differentiation. First, BMP induced apoptosis within interdigital space there by separating the digits,

and secondarily its participation in chondrogenesis via SOX9 upregulation and maintaining the digit-associated FGF in overlying AER for continued digital outgrowth.

Intermittent apoptosis of AER controlled by SHH and BMP results in division of digital primordia into phalanx forming region and interdigital (ID) region. The interdigital mesenchyme contains BMP abundantly which had role in activating chondrogenesis and formation of interzone (future joint) by acting through SOX9 (*fig 12*)<sup>7</sup>.

In several animals like ducks and bats, there was persistent interdigital webbing present. In these animals there was BMP inhibitor Gremlin (GREM) expressed in the interdigital region which inhibit apoptosis. Ectopic overexpression of these BMP inhibitors in limb mesenchyme and persistence function of FGF in AER or mesoderm inhibits interdigital apoptosis and result in syndactyly. Mutations in Noggin (NOG), a BMP inhibitor, are clinically associated with joint synostoses, syndactyly, and polydactyly, reflecting the spectrum of BMP functions. In Apert's syndrome there was mutation of FGF receptor 2 which result in increased activation affinity of FGF ligand which were diffusely present in limb mesenchyma. This result in constant stimulus keeping the FGF always on there by suppressing BMP mediated apoptosis result in syndactyly in Apert's syndrome.

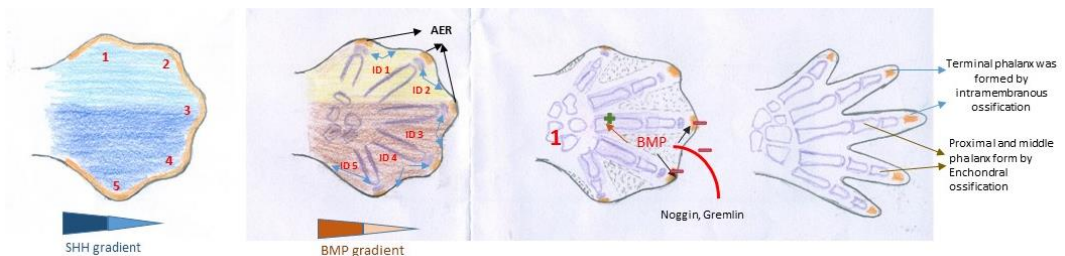


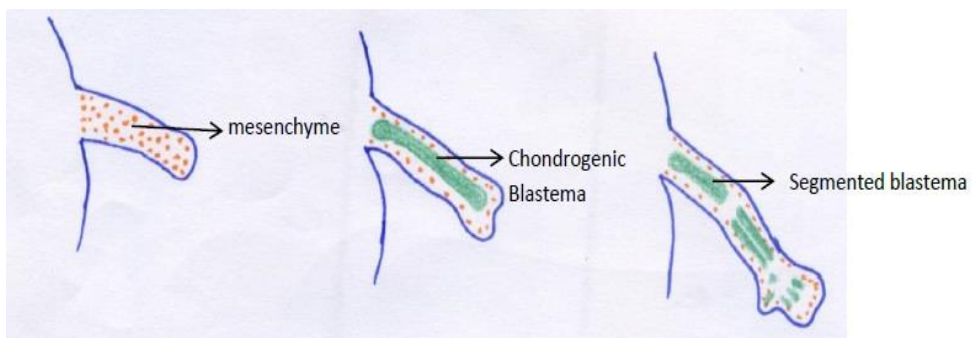
Fig 12: From left to right: A) Hand plate showing gradient of SHH regulated by ZPA. B) Digital primordia divided into interdigital region (ID) and phalanx forming region with BMP gradient. C) Role of BMP in regulating chondrogenesis of phalanges, Interzone formation and regulating AER through SOX9.

## **DEVELOPMENT OF SKELETON:**

### **Formation of Bones:**

During 4<sup>th</sup> week of intra uterine life mesenchymal cells in the centre of the limb bud swell (hypertrophy) to form chondrocyte blastema under low oxygen tension which forms chondrocytes. Initially the blastema is a long unsegmented bar extending from arm to hand which later is segmented and form each bone's cartilage anlage (*fig 13*). All the cartilage anlagen of long bones in the embryo resemble their mature form.

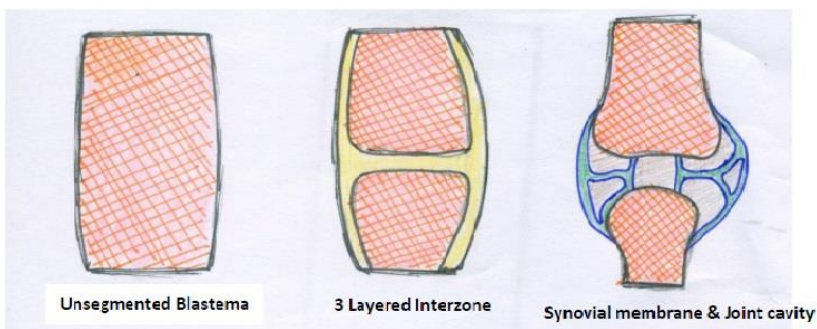
The cells in blastema rapidly proliferate and grow both radially and longitudinally until they face resistance from adjacent cells which are flattened to form perichondrium initially. This perichondrium is formed early in the diaphysis and later in the metaphyseal region which is the reason for broader ends while the shaft is narrower. Perichondrium is replaced by fibrous periosteum later. Unlike long bones, carpal bones have round cells and proliferate slowly without formation of flattened cells. All the upper limb bones are formed by endochondral ossification while tufts of terminal phalanges are formed by membranous ossification where bone is directly formed (*fig 12*). Clavicle and scapula are not formed in the limb bud.



*Fig.13: Cartilage blastema formation and segmentation*

### **Formation of Joints:**

Dense mesenchymal cells without hypertrophy at the ends of blastemas mark the future sites of joints. There will be formation of tri layered structure between two adjacent blastemas with loosely arranged cells in the middle layer. This is called an “Interzone” (*fig 12,14*). This three layered interzone having central loose mesenchyma which cavitates to form joint fluid and the surrounding dense mesenchyma would form articular cartilage. These development in the joint area coincides with the progression on muscular development to the point of myofibril contractions and motion. As the surrounding mesenchyme forms synovial and capsular tissues in the middle layer the dense plate on either side gets chondrified to become future articular surfaces. It proceeds to proper joint only by embryonic muscular activity. These embryonic movement is required throughout the development initially for formation of joint, finally for modelling and in later stages for maintenance of joint. Without these motions, articular surfaces flatten and the joint cavity fills with compact fibrous tissue which result in stiff joints as seen in Arthrogyrosis multiplex congenita.



*Fig. 14: Joint formation from an 'Interzone'.*

### **Formation of Muscles:**

During 6<sup>th</sup> week of intra-uterine life, under high oxygen tension the mesenchyme in the periphery forms the muscle blastema over cartilage

blastema. In human embryo the somites won't contribute to formation of limb skeleton but forms the trunk skeleton unlike lower animals<sup>6</sup>. Myoblasts are the muscle stem cells which fuse to form myotubules. Myotubule number is constant throughout but muscle increases in size by elongation of tubules. During the development the proximal muscles leave the blastema first and the superficial muscles leave earlier than the deep muscles. FDS (sublimus) unlike other forearm muscles, is formed from volar hand blastema and ascends to its origin (medial epicondyle) passing over FDP and median nerve. Palmaris longus is identifiable later than other forearm muscles. Hence, FDS and PL are considered to be phylogenetically newer muscles<sup>2</sup>.

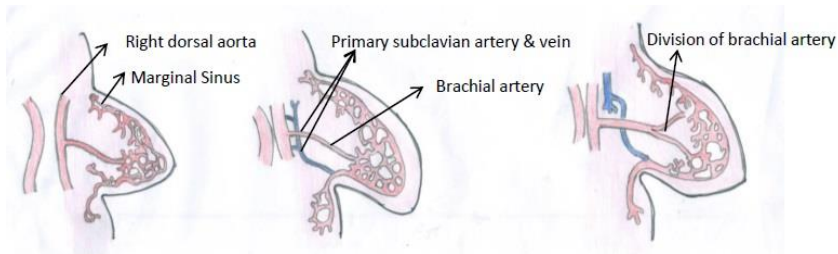
### **Formation of Nerves:**

Nerve development commences with formation of neural plate from ectoderm at 21 days. Neural plate folds to form neural tube which forms spinal cord in future. The early cord has 2 types of proliferating cells which send motor and sensory nerves to limb bud during 3<sup>rd</sup> week. Brachial plexus is formed by fourth week and ingrowth in to limb bud occurs. Cell bodies of these cells send long axons which have distal enlarged tips with highly motile filopodia. This tip is called a growth cone which advances till elbow by 5<sup>th</sup> week and reach hand by 7<sup>th</sup> week. When growth cone comes in contact with the target organ it forms nerve.

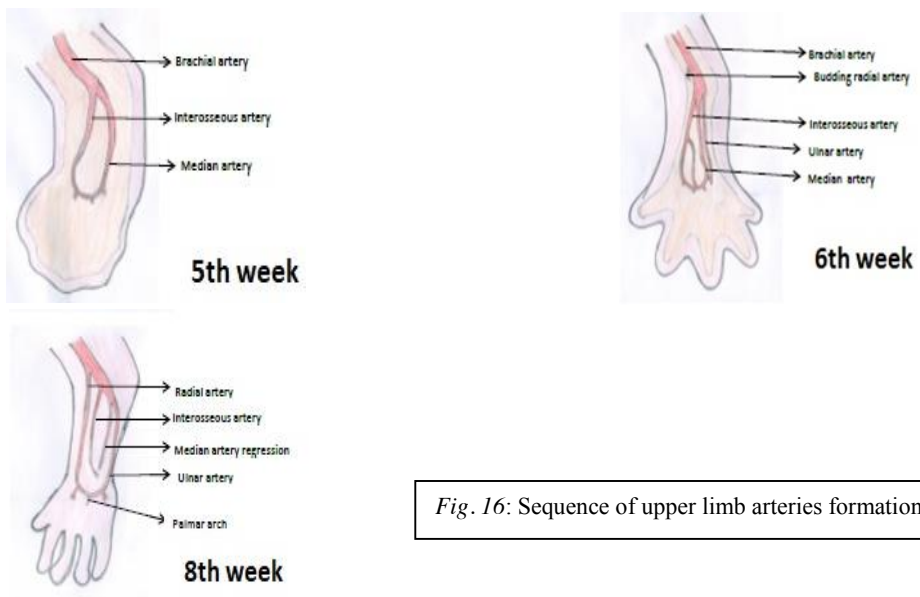
### **Formation of Vascular System:**

Cardiovascular system is the first functional system developed in the embryo. Hemangioblasts are the stem cells found in early mesenchyme which form vascular plexus in the limb bud. This plexus forms marginal sinus in the peripheral mesenchyme just under ectoderm, under the influence of AER (*fig 15*). This network forms discrete venous and lymphatic channels. The marginal sinus disintegrates to form venous system for return of blood to major thoracic vessels.

By sprouting off major vessels in the thorax the vascular channels grow into limb bud during 4<sup>th</sup> week. By 5<sup>th</sup> week brachial artery is seen and it continues as interosseous artery in the forearm (*fig 16*). All major distal arteries branch off from brachial artery and median artery is the earliest one to form followed by ulnar artery. The radial artery is the last one to form. The median artery will regress to form artery supplying the median nerve.



*Fig.15: Formation of marginal sinus under AER influence*



*Fig. 16: Sequence of upper limb arteries formation*



## REFERENCES:

1. Douglas M. Sammer, Kevin C. Chung .Congenital Hand Differences: Embryology and Classification. *Hand Clin* 25 (2009) 151-156.
2. Amit Gupta, Simon PJ Kay, Luis R Scheker.The Growing Hand: Diagnosis and Management of the Upper Extremity in Children, 1<sup>st</sup> edition. ISBN-13: 978-0723421337, ISBN-10: 0723421331
3. Gilbert, SF (2003) *Developmental Biology*.7<sup>th</sup> edition.
4. Kerby C. Oberg, Jennifer m. Feenstra et al. *Developmental Biology and Classification of Congenital Anomalies of the Hand and Upper Extremity*. *J Hand Surg* 2010; 35A:2066-2076.
5. Al-Qattan MM, Kozin SH.Update on Embryology of the Upper Limb. *J Hand Surg* 2013; 38A:1835-1844.
6. Inderbir Singh. *Human Embryology*. 11<sup>th</sup> edition.
7. Oberg KC, Tonkin MA. *Developmental biology and classification of congenital anomalies of the hand and upper extremity*. *J Hand Surg* 2010; 35A:2066-2076.