

Anatomy of the Triangular Fibrocartilage Complex (TFCC)

Dr Karan Choudhry (Senior registrar)

Dr Ravi Bharadwaj (Consultant)

Hand and Wrist Surgery Unit

Apollo Gleneagles Hospital

Kolkata



Introduction:

The Triangular fibrocartilage complex (TFCC) is an incredibly complex structure that provides intrinsic stability to the distal radioulnar joint and the ulnocarpal aspect of the wrist. It is named so because of its triangular anatomic as well as its structural shape (Figure 1). Injuries to the TFCC are the commonest cause of ulnar side wrist pain- the so called- 'Back pain of Hand Surgery'. It can get injured by a fall on outstretched hand in hyperextension and pronation of the wrist joint. It is often associated with fractures of the distal end of the radius. (1)

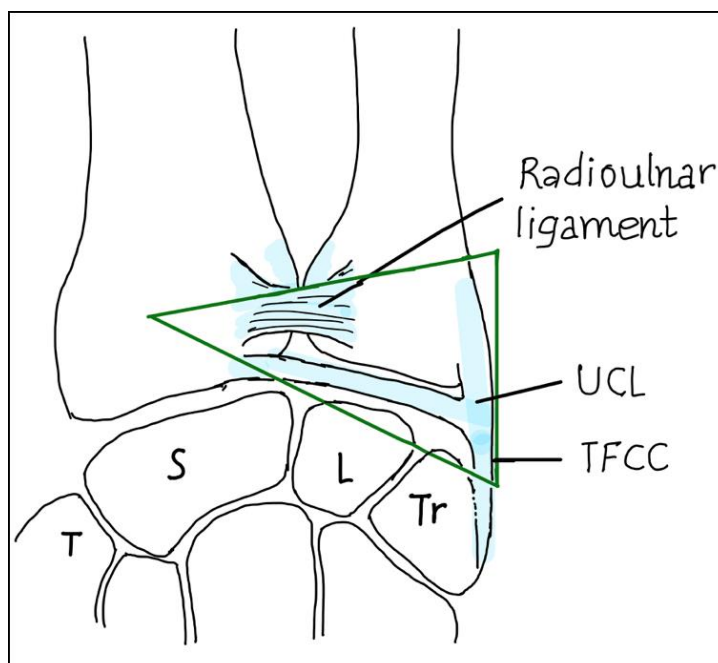


Figure 1: Structural arrangement of the TFCC

The TFCC comprises of (1) [Fig 2 and 3]:

1. Superficial and deep limbs of the dorsal and volar radio-ulnar ligaments.
2. Fibro-cartilaginous disc and ulno-meniscal homologue.
3. Extensor Carpi Ulnaris (ECU) tendon sub-sheath.
4. Ulnocarpal ligaments on the volar aspect i.e. ulno-lunate and ulno-triquetral ligaments.
These ligaments originate from corresponding carpus and insert on the palmar aspect of the radio-ulnar ligament and the fovea.
5. Ulnar collateral ligament (UCL).

TFCC plays a vital role in maintaining distal radio-ulnar joint (DRUJ) stability. The TFC (Triangular fibrocartilage) consisting of dorsal and volar radio-ulnar ligaments, the fibrocartilage disc and meniscal homologue serves as intrinsic stabilizers to the DRUJ. On the other hand, the ECU sub-sheath along with the distal fibres of the interosseous membrane and pronator quadratus act as extrinsic stabilizers of the DRUJ. Our understanding of the anatomy and physiology of this complex structure has improved vastly in the recent few years as a result of newer cadaveric, histological and biomechanical studies along with improvements in arthroscopic and imaging techniques. (2,3,4,5)

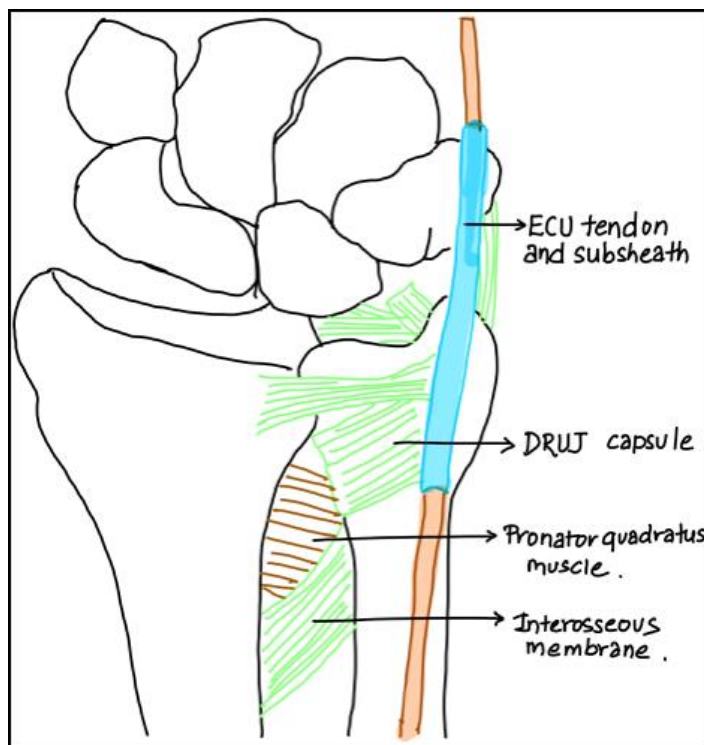


Figure 2: Schematic diagram of anatomy seen from the dorsal aspect of the DRUJ

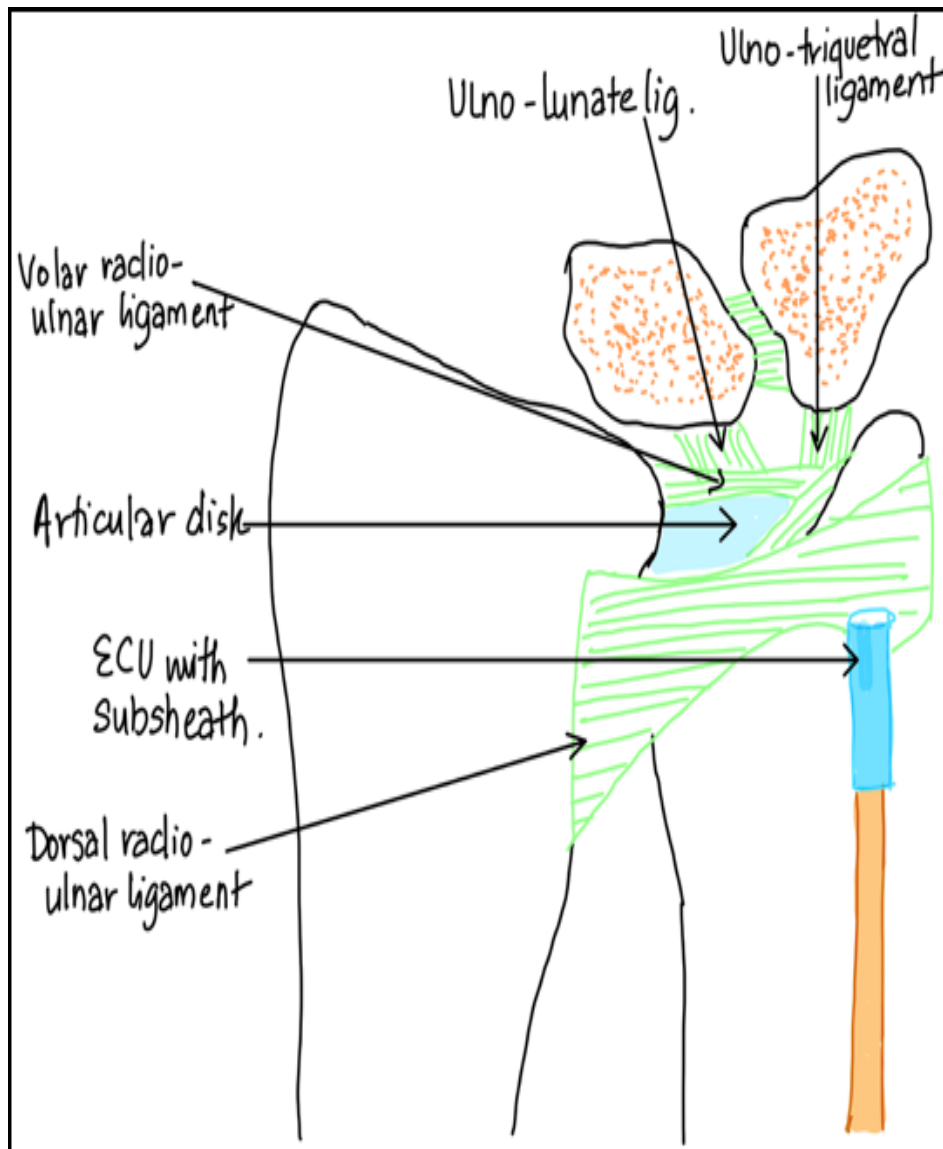


Figure 3: Schematic diagram of the internal view of TFCC (section of ECU removed)

Salient Histology of the TFC:

Origin:

Concave sigmoid notch medial to the distal end radius from its hyaline cartilage.

Insertion:

1. Fovea (Vertically oriented Sharpey's fibres).
2. The base of ulnar styloid (Horizontally-oriented Sharpey's fibres).
3. ECU sub-sheath (Sharpey's fibres) (3).
4. Ulnocarpal ligaments.

Central disc:

- It occupies 80% area and is composed of fibrocartilage.
- Comprises of type 1 collagen bundles with interspersed chondrocytes. (3)
- It is avascular.
- It has poor healing potential.
- It attaches to the hyaline cartilage of the sigmoid notch. (3)

Peripheral disc:

- It comprises of the outer 20% area of the TFCC.
- Vascular connective tissue along with fibroblasts secreting proteoglycans and extracellular matrix.
- It has good healing potential.

Blood supply (5) [Fig 4]:

- Branch of the posterior interosseous artery,
- Ulnar artery,
- Intra-medullary supply from the head of the ulna.

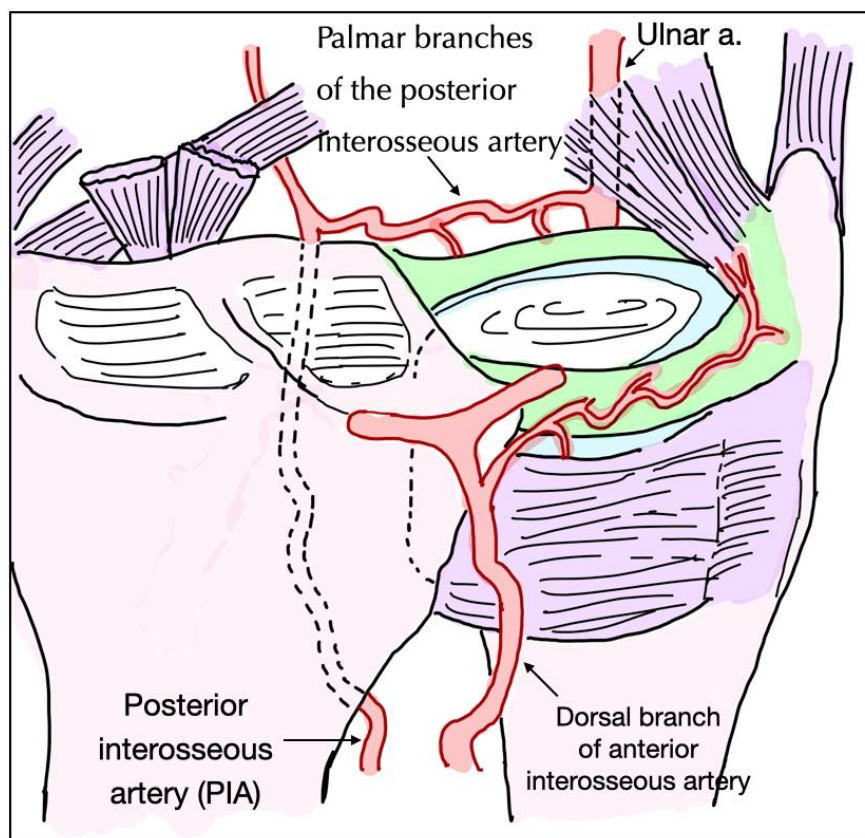


Figure 4: Microvasculature of the TFCC

Various authors have described the structure and function of the TFCC based on their observations.

The two-dimensional structure of the TFCC by Palmer and Werner (1981) (6)

- TFCC formed by disc proper, meniscus homologue, volar and dorsal radio-ulnar ligaments, ulnar collateral ligament, the floor of the ECU, ulno-lunate and ulna triquetral ligaments [Fig 5].

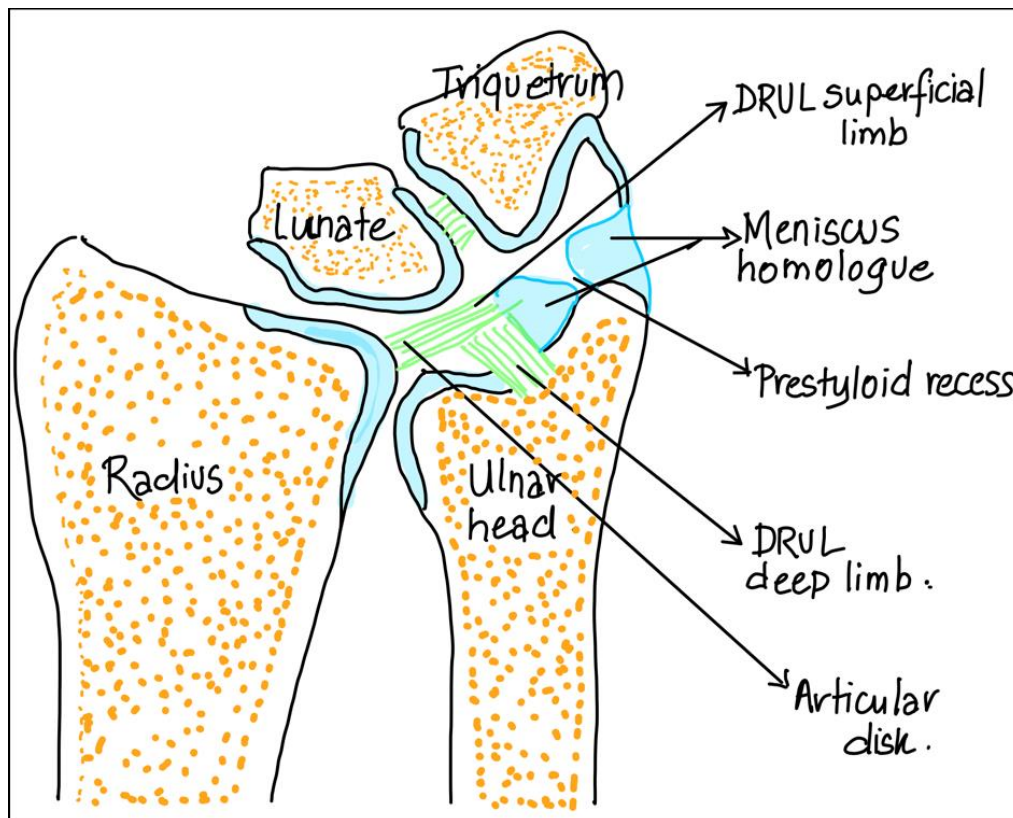


Figure 5: *TFCC anatomy in coronal section*

- Volar and dorsal radio-ulnar ligaments surrounded the disc proper which in turn inserted on the ulna styloid. They were described as structures that supported the TFCC, rather than true ligaments [Fig 6].

The function of superficial and deep components of the volar and dorsal ligaments and the role of disc proper in DRUJ mechanics was not well understood then.

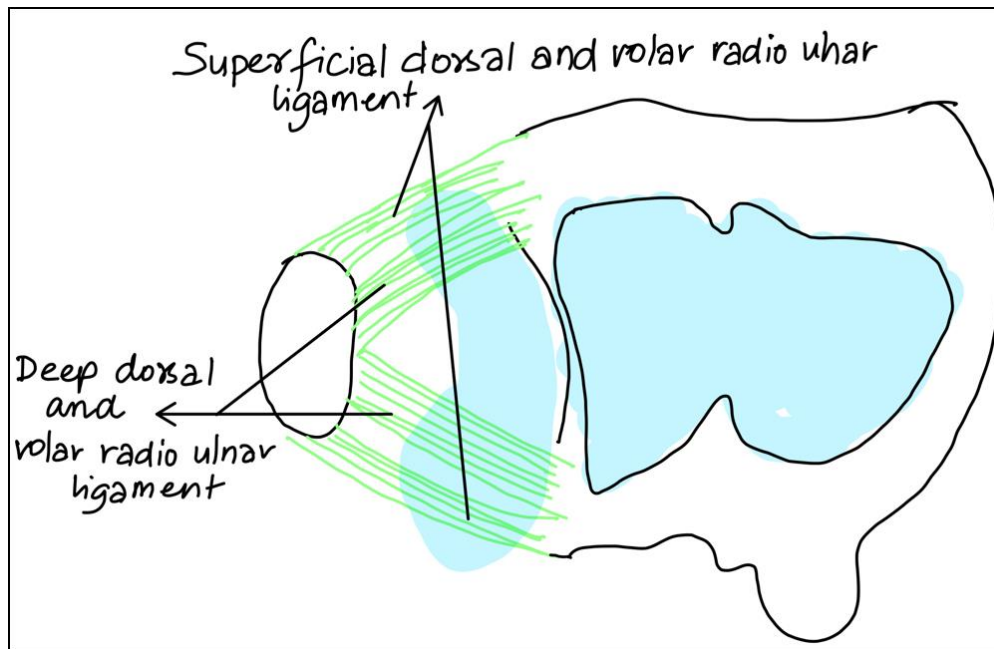


Figure 6: Orientation of Superficial and deep volar-dorsal radioulnar ligaments.

Three-dimensional structure of the triangular fibrocartilage complex of Nakamura (“Hammock” concept/ suspension theory) (4)

- Many anatomical and histological facts about the TFCC were documented based on cadaveric studies by Nakamura et al (2,3,4). It played a vital role in improving the understanding of the anatomy and the dynamics of the TFCC.
- TFCC is composed of fibrocartilage and attaches loosely to hyaline cartilage contributing to the wrist mobility and flexibility. Also, it firmly attaches to bone periosteum by Sharpey’s fibres (3).
- The TFCC is divided into 3 zones (2) [Fig 7]:
 1. Proximal portion: Its insertions into the triangular foveal ligament. It contributes to DRUJ stability.
 2. Distal portion: Represents the “hammock” supporting the carpus.
 3. Ulnar collateral ligament.

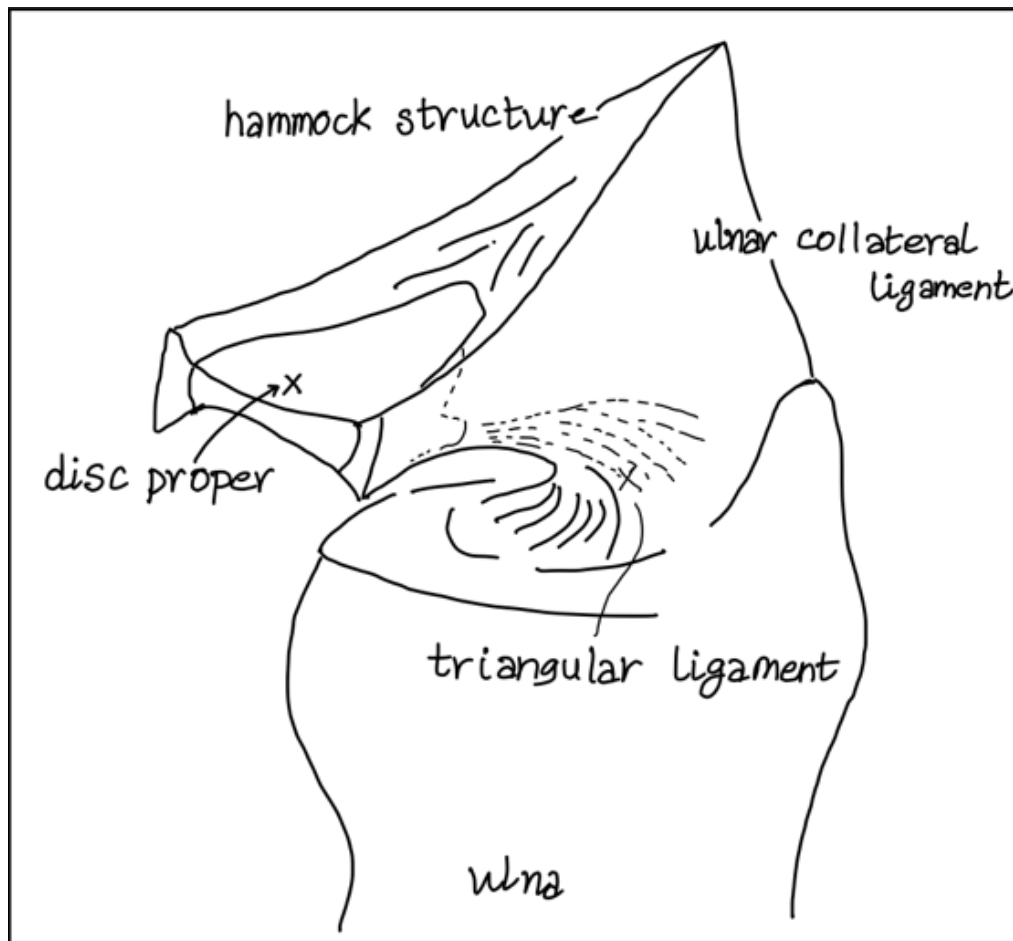


Figure 7: Diagram explaining the 'Hammock concept' of structure and function of the proximal triangular ligament, distal hammock structure and the ulnar collateral ligament (4).

- The three components suspend each other and their suspension arrangement and loose internal structure allows for both mobility and stability of the ulnar side of the wrist.
- During forearm rotation, the central articular disc remains immobile, whereas the triangular ligament twists at its foveal insertion. Dynamic changes occur at the ulnar aspect of the TFCC and UCL. (2)
- The proximal portion of the TFCC reinforced the hammock structure which in turn supported the carpus. The morphology of the proximal portion of the TFCC was categorised as fan shape, V-shape or funnel shape in appearance [Fig 8]. (4) Its volar and dorsal margins were found to be thick and serve as stabilizing ligaments.

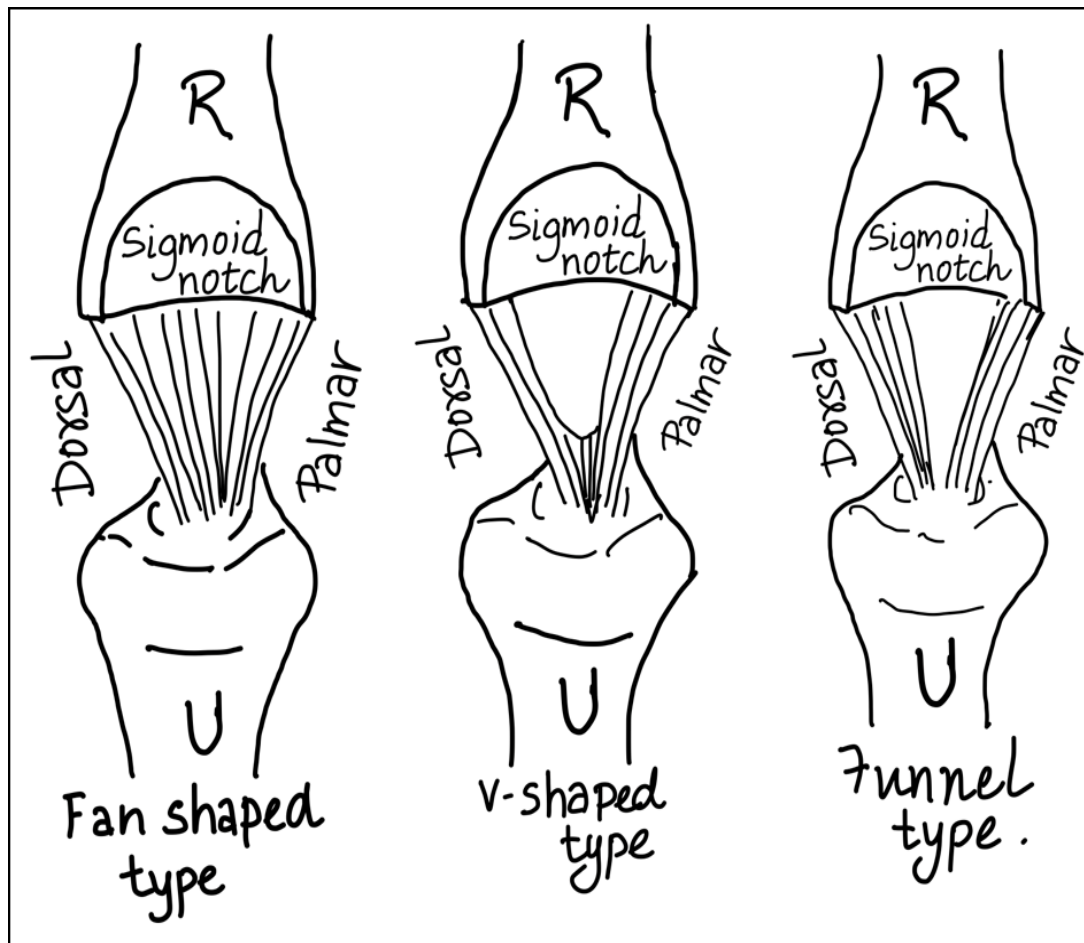


Figure 8: Anatomical pattern variations in the proximal portion of the TFCC.

- Fan-shaped type; V-shaped type and Funnel-shaped type.

- The ulnar collateral ligament was described as the floor of the ECU and surrounding loose ligamentous structures. Also, UCL underwent deformation during pronation and supination. (2)
- Ulnar joint capsule originated from the tip and middle portion of the ulna styloid and then coalesced with the meniscus homologue to constitute the ulnar wall of the TFCC (3).
- In extreme movements, the DRUJ capsule prevents the joint dislocation. (9)

Iceberg concept [Fig 9] (7):

- Further studies in the anatomy and biomechanics couples with the advances in the surgical treatment of the TFCC injuries especially the wrist arthroscopy brought about changes in the perspective of the TFCC.
- TFCC was further divided into proximal component (pc-TFCC) and distal component (dc-TFCC). This concept was proposed focusing on the nature of TFCC 1B avulsion injury.

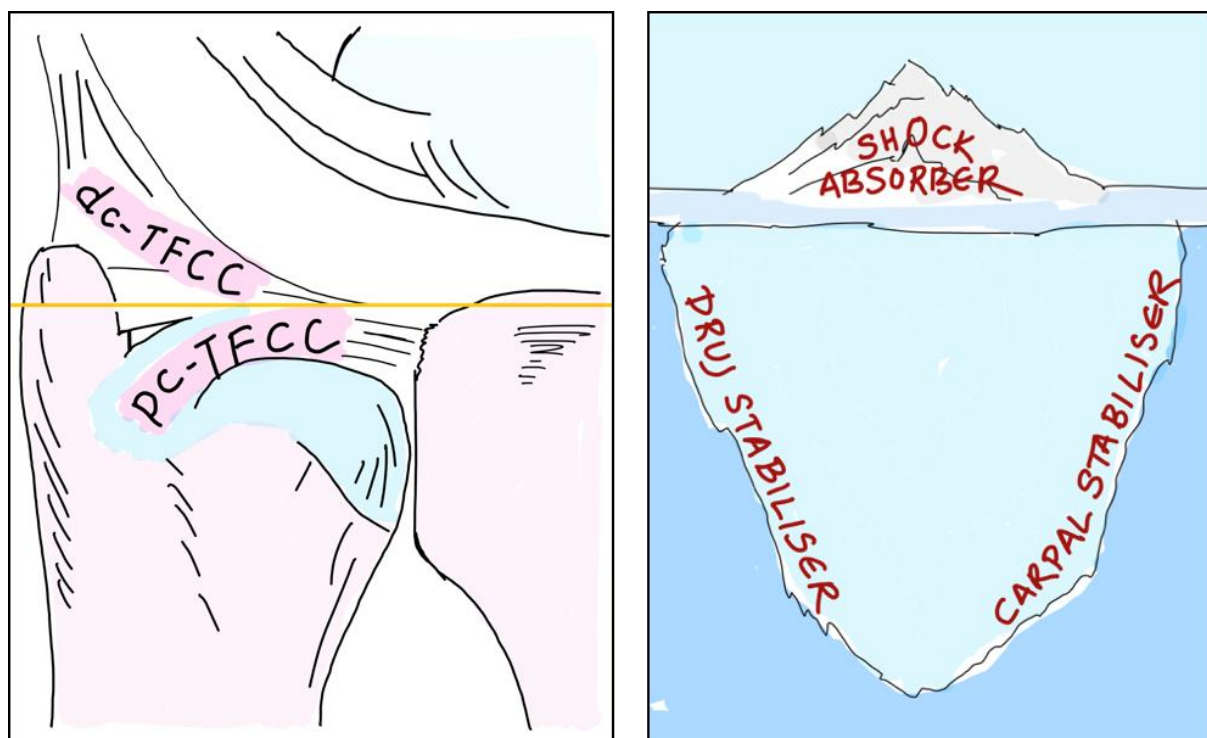

Figure 9 (a and b): Iceberg concept (7)

(a): TFCC is divided into (1) proximal component (pc-TFCC)- foveal attachment of the proximal triangular ligament. (2) Distal component (dc-TFCC)- including the UCL and hammock structure.

(b): The portion of TFCC that is visible during wrist arthroscopy functions as a shock absorber, however, the portion that is not visualized directly serves to provide DRUJ and proximal carpal row stability.

- Pc-TFCC injuries cause DRUJ instability leading to reduced forearm rotation, ulnar sided wrist pain, and reduced grip strength. Also, persistent DRUJ instability caused dissatisfaction and lead to high reoperation rates. (7)
- During the radio-carpal scope, the dc-TFCC represents the emerging tip of the iceberg and serves as a shock absorber. (7)
- The most important portion of the TFCC was not visible directly through radiocarpal portals. Indirect evidence of it is obtained by hook sign (7). The pc-TFCC signifies the submerged portion of the iceberg, which rather holds greater functional importance. They can be visualized by DRUJ portals. (7)

Biomechanics and clinical significance:

- Analysis of the force transmission across the wrist joint demonstrated an approximate 80% pass through the radius and 20% pass through the ulna (8,9).
- Forearm rotation causes drilling movements of the ulna over the ulnar carpus, which is responsible for degenerative changes. Also, the ulnar variance is contributory (10).
- The functioning of TFCC has a close association with the stabilization of DRUJ and the ulnocarpal joint (5,6).
- Central disc distributes mechanical stresses on the proximal carpal row.
- TFCC provides a gliding surface allowing 6 degrees of movements at the wrist: flexion, extension, supination, pronation, radial and ulnar deviation (12).
- MR arthrography allowed study of the dynamic changes in the ulnar aspect of the radio-ulnar ligament in different positions of the forearm, translation of the ulna was observed (11). Extreme rotations cause uncovering of the TFCC from the distal ulna, predisposing it to injuries in such positions (8).

- Dynamic changes occurring in the superficial and deep Volar Radio-Ulnar ligament (VRUL) and Dorsal Radio-Ulnar Ligament (DRUL) in different forearm position [Fig 10].

a. During pronation:

- Dorsal translation of the ulna (3).
- Superficial fibres of the DRUL and deep fibres of the VRUL tighten (1).

b. In mid prone:

- DRUJ remains congruent at the sigmoid notch.
- Superficial and deep fibres of VRUL and DRUL are equivocal.

c. During supination:

- Volar translation of the ulna.
- Superficial fibres of the VRUL and deep fibres of the DRUL tighten.

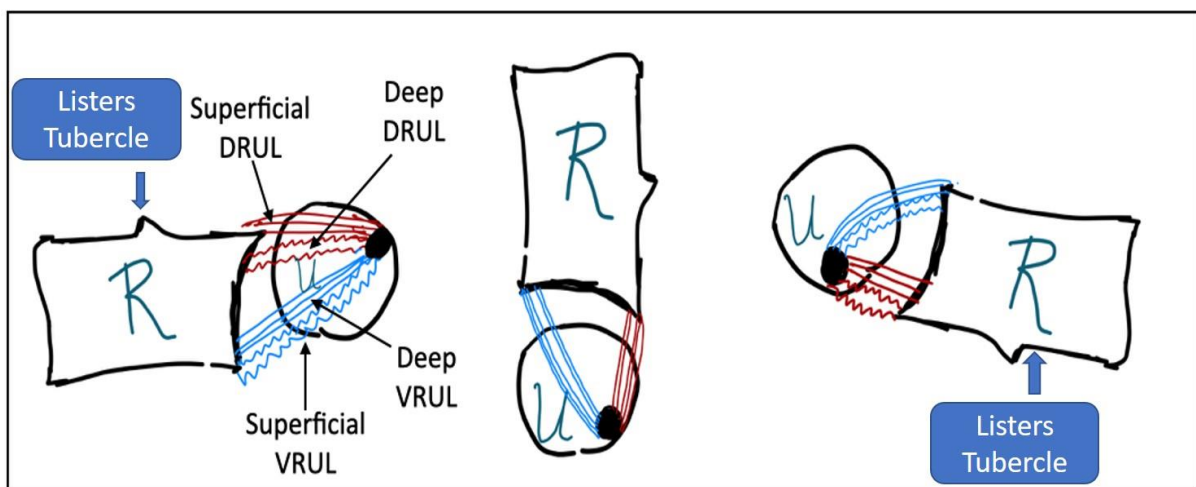


Figure 10: Diagrammatic representation of the dynamic changes occurring in the superficial and deep VRUL and DRUL in different forearm position- Pronation- Mid-prone - Supination.

- Thus, it is imperative to do an examination for DRUJ stability in all the 3 positions to understand the location of injury. (12) Test in full pronation would test the integrity of the deep volar (and superficial dorsal) fibres of the radio-ulnar ligament whereas in full supination the integrity of the deep dorsal (and superficial volar) fibres is assessed.

The rationale behind the important signs performed during arthroscopic examination of the wrist:

1. Trampoline sign:

Loss of normal elasticity of the articular disc while checking with a hook probe through 6 R portal.

Inference: Positive in distal or complete tears. Negative in isolated proximal lesions.

2. Hook sign (7):

A wave effect created while the TFCC is lifted off from its proximal attachment and pushed to the radial side while examining with a probe through a 6 R portal.

Inference: Positive in a complete tear. Equivocal in isolated proximal or distal tears.

3. Ghost sign (Fontes) (12):

While the hook is inserted in the DRUJ portal, a wave effect is created by lifting off the TFCC from beneath it.

Inference: Positive in isolated proximal tears. Negative in isolated distal tears.

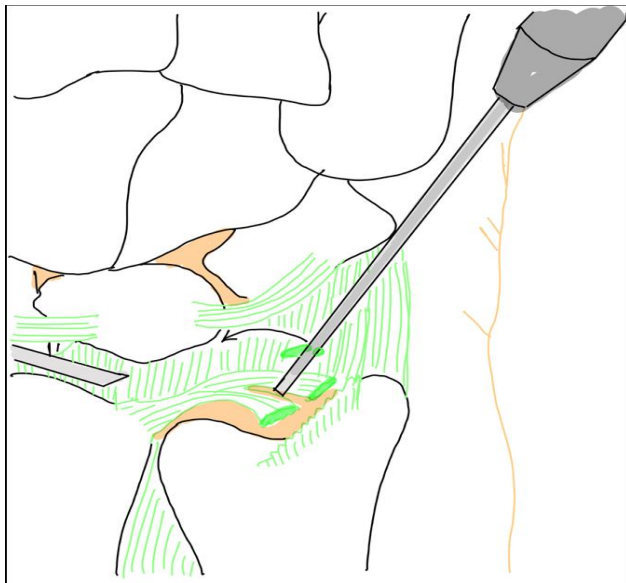


Figure 11: Visualizing a foveal avulsion through the 3-4 portal and using a hook through 6R portal to pull the ligament through its insertion.

Conclusion:

TFCC plays a vital role in wrist stability and load transmission. The peripheral 20% of the TFCC is vascularised and thus has good healing potential. Thus, good results are obtained in repairs done in peripheral zones. The three-dimensional structural orientation of the TFCC helps us understanding the location of its tear and implication on ulnar sided wrist stability.

References:

1. Hagert CG. Distal Radius Fracture and the Distal Radioulnar Joint--Anatomical Considerations. *Handchir Mikrochir Plast Chir* 1994 Jan;26(1):22-6.
2. Nakamura T, Yabe Y, Horiuchi Y. Functional anatomy of the triangular fibrocartilage complex. *Journal of Hand Surgery*. 1996 Oct;21(5):581-6.
3. Nakamura T, Takayama S, Horiuchi Y, Yabe Y. Origins and insertions of the triangular fibrocartilage complex: a histological study. *The Journal of Hand Surgery: British & European Volume*. 2001 Oct 1;26(5):446-54.
4. Nakamura T, Makita A. The proximal ligamentous component of the triangular fibrocartilage complex: functional anatomy and three-dimensional changes in the length of the radioulnar ligament during pronation and supination. *Journal of hand surgery*. 2000 Oct;25(5):479-86.
5. Bednar MS, Arnoczky SP, Weiland AJ. The microvasculature of the triangular fibrocartilage complex: its clinical significance. *The Journal of hand surgery*. 1991 Nov 1;16(6):1101-5.
6. Palmer AK, Werner FW. The triangular fibrocartilage complex of the wrist—anatomy and function. *Journal of Hand Surgery*. 1981 Mar 1;6(2):153-62.
7. Atzei A, Luchetti R. Foveal TFCC tear classification and treatment. *Hand clinics*. 2011 Aug 1;27(3):263-72.
8. Bruckner JD, Alexander AH, Lichtman DM. Acute dislocations of the distal radioulnar joint. *Instructional course lectures*. 1996;45:27-36.
9. Tuly E: *Sports physiotherapy – Applied science and practise in Hand and Wrist*. 1st Edition., Churchill Livingstone, Melbourne; 1995, pp 439-442.

10. Joshi SS, Joshi SD, Jadhav SD, Athavale SA, Waghmode PS. Triangular Fibrocartilage Complex (TFCC) of the wrist: some anatomo-clinical correlations. J Anat Soc India. 2007;56(2):8-13.
11. Pfirrmann CW, Theumann NH, Chung CB, Botte MJ, Trudell DJ, Resnick D. What happens to the triangular fibrocartilage complex during pronation and supination of the forearm? Analysis of its morphology and diagnostic assessment with MR arthrography. Skeletal radiology. 2001 Dec 1;30(12):677-85.
12. Mathoulin C Anatomy of the Triangular Fibrocartilage complex: Current concepts: Wrist Arthroscopy Techniques; Theime 2015; 37-41