

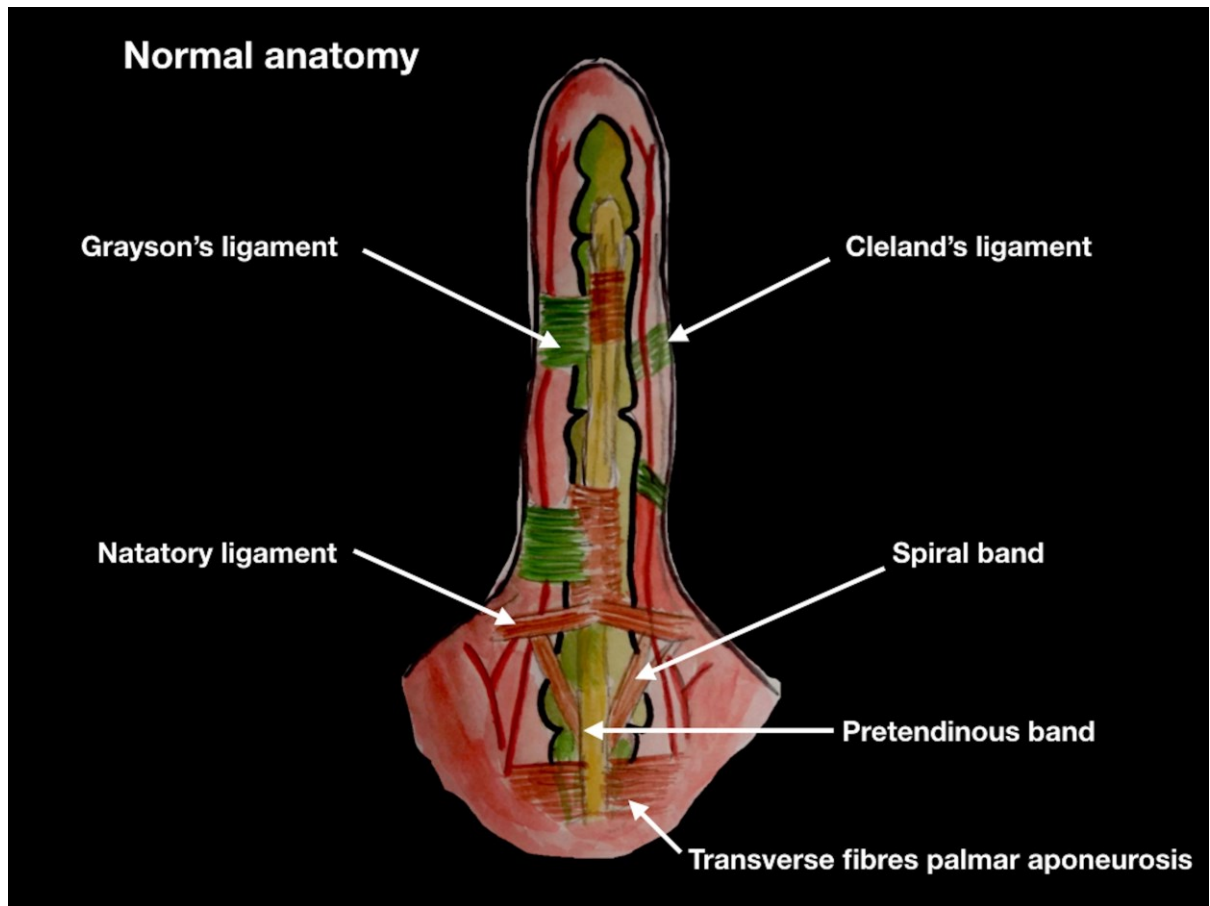Fig 1 -- Normal relationship of integumentary structures in the digit and palm

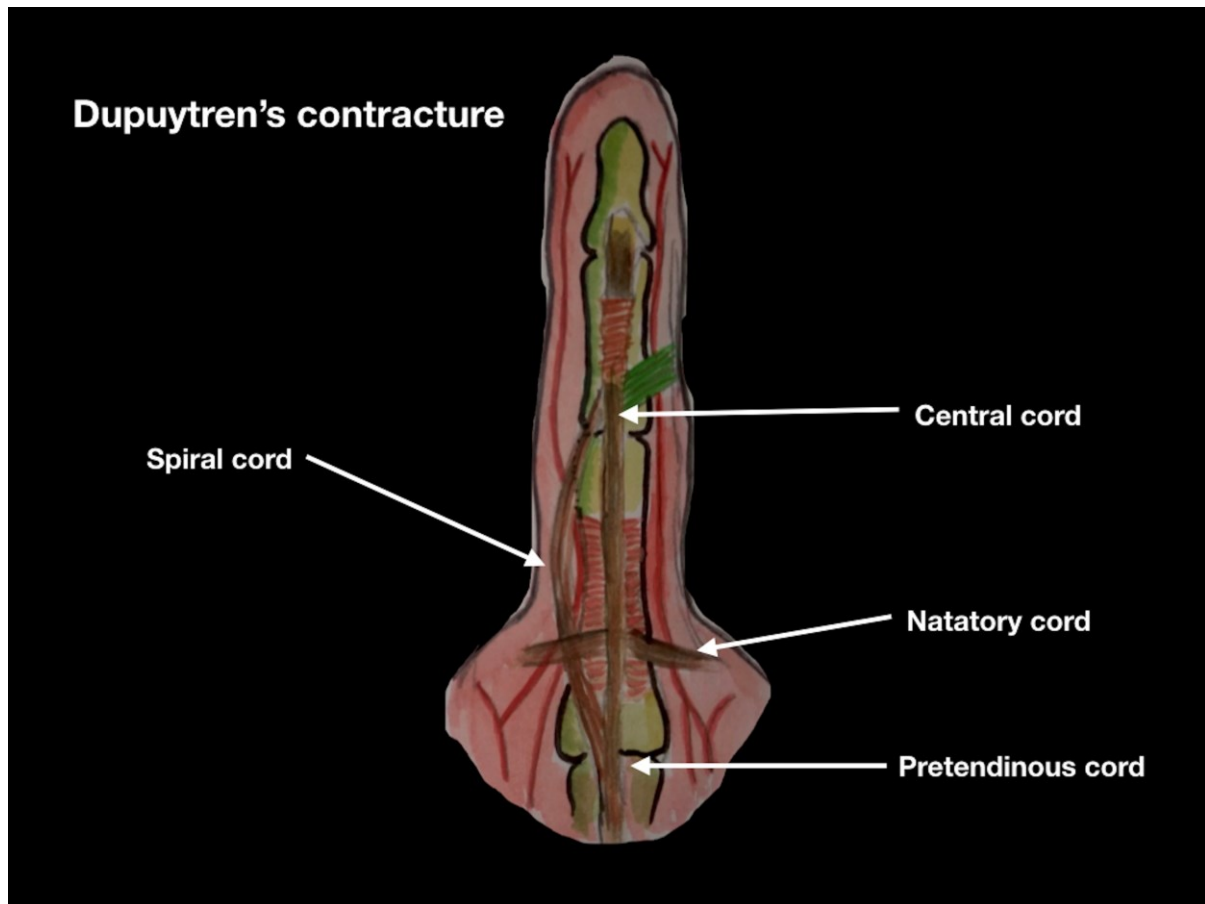


Fig 2 – Pathologic anatomy in Dupuytren's contracture. The spiral cord can be seen impinging on the neurovascular bundle and displacing it to an abnormal position.